



PATIENT

Bailey Ostrowski

SPECIES

Canine

BREED

Yorkie Mix

SEX

MN

AGE

13 y

WEIGHT

7.3 lb

INTERPRETED BY

Keith Blass, DVM, MS,
DACVIM (Cardiology)

IMAGING PERFORMED BY

Brandi Kurzowski

HOSPITAL NAME

Corfu VC

REFERRING VET

Dr. Gardner

INVOICE

DATE

4/7/26

PRESENTING CLINICAL SIGNS

Historic left ventricular dilation. Receiving benazepril. Also takes temaril P and Tussigon for a historic cough.

ECHOCARDIOGRAPHIC FINDINGS

2D, M-mode, and Doppler study.

Left atrial size is normal. The mitral valve appears normal, though trace mitral regurgitation is present. Left ventricular dimensions are normal. Left ventricular systolic function is hyperdynamic. The aorta and aortic valve are normal. Right atrial and right ventricular dimensions are normal. The tricuspid valve is normal. The pulmonary artery and pulmonic valve are normal. No shunting lesions are visualized. No pericardial effusion or cardiac masses are seen.

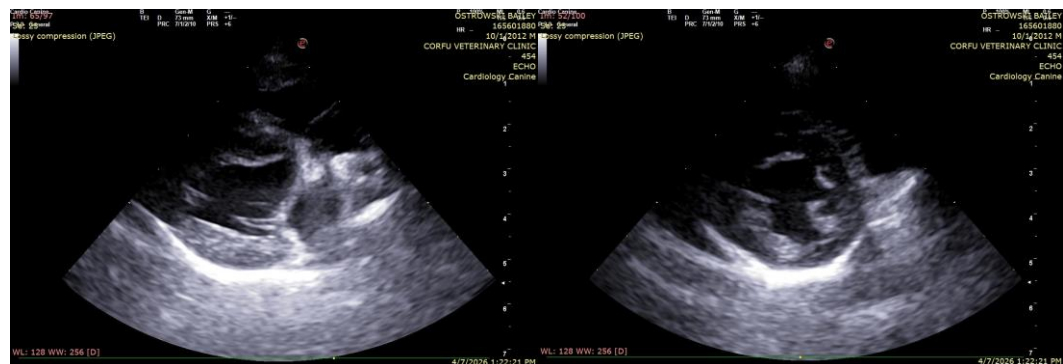
ASSESSMENT/RECOMMENDATIONS

Normal echocardiogram

This examination demonstrates no evidence of structural heart disease, as the previously noted left ventricular dilation is not present in today's exam.

No therapy is recommended based on this exam.

A recheck echocardiogram is recommended if new physical exam and/or clinical abnormalities suggestive of cardiac dysfunction develop.



The information and recommendations provided are based on the images presented by the referring



PATIENT

Bailey Ostrowski

SPECIES

Canine

BREED

Yorkie Mix

SEX

MN

AGE

13 y

WEIGHT

7.3 lb

INTERPRETED BY

Keith Blass, DVM, MS,
DACVIM (Cardiology)

IMAGING PERFORMED BY

Brandi Kurzowski

HOSPITAL NAME

Corfu VC

REFERRING VET

Dr. Gardner

INVOICE

DATE

4/7/26

veterinarian/sonographer. No evaluation can be communicated regarding pathology that was not visible in the image/video clips provided.

Thank you for this referral. If the clinical or image interpretation does not parallel your findings or if I can be of any further assistance please contact me.

Keith Blass, DVM, MS, DACVIM (Cardiology) info@SonoPath.com